



The first case of surgical myocardial revascularization and endarterectomy of the right carotid artery in the same procedure in a patient with haemophilia A

Prvi slučaj hirurške revaskularizacije miokarda i endarterektomije desne karotidne arterije u istom aktu kod bolesnika sa hemofilijom A

Nataša Janković*, Dragan Simić†‡, Aleksandar Mikić*‡, Miloš Matković*,
Petar Vukičević§||, Ivo Elezović*¶

Clinical Center of Serbia, *Department of Cardiac Surgery, †Department of Cardiology, ‡Department of Hematology, Belgrade, Serbia; University of Belgrade, §Faculty of Medicine, Belgrade, Serbia; Military Medical Academy, §Clinic for Cardiac Surgery, Belgrade, Serbia; University of Defence, ||Faculty of Medicine of the Military Medical Academy, Belgrade, Serbia

Abstract

Introduction. Haemophilia A is the most common hereditary coagulation disturbance occurring due to the lack of coagulation factor VIII. It is widely accepted that people with haemophilia have a reduced incidence of coronary artery disease, potentially because of the protective effect of the impaired coagulation against the pathogenic mechanisms of the acute coronary syndrome. **Case report.** A 53-year-old man with mild haemophilia [FVIII 22% (mild form: more than 5%–40% of normal)] was hospitalized because of frequent anginal pain at rest. Selective coronary angiography revealed a severe three-vessel coronary disease. A need for urgent surgical revascularization was indicated. The color duplex scan showed the existence of hemodynamically significant stenosis on the right internal carotid artery. After consulting a haematologist, a cardiac surgeon, and a vascular surgeon, it was concluded that due to high bleeding risk, the patient should undergo an endarterectomy of the right carotid artery and a triple aortocoronary bypass in the same procedure. Procedures

were performed with a substitution of FVIII concentrate. The patient firstly underwent the endarterectomy of the right carotid artery. Then, the left mammary artery graft was implanted to the left anterior descending artery as well as the venous grafts to the first obtuse marginal artery and posterior descending branch. There were no complications. During the revascularization, there was no need for blood transfusion, nor was there excessive bleeding in the postoperative period. The patient was discharged with antithrombotic therapy (aspirin, 50 mg). **Conclusion.** Patients with haemophilia are not protected against the development of atherosclerosis. Cardiac surgery in these patients presents a unique challenge for medical teams in securing haemostasis. Adequate substitution with factor VIII concentrate provides adequate haemostasis and the possibility for treatment with antiplatelet therapy.

Key words: hemophilia a; coronary disease; coronary artery bypass; endarterectomy, carotid; cardiovascular surgical procedures; treatment outcome.

Apstrakt

Uvod. Hemofilija A je najčešći nasledni poremećaj koagulacije koji nastaje zbog deficita faktora VIII. Opšte je prihvaćeno da ljudi sa hemofilijom imaju smanjenu incidencu koronarne bolesti, uglavnom zbog protektivnog efekta narušenog sistema koagulacije nasuprot patogenetskim mehanizama za razvoj akutnog koronarnog sindroma. **Prikaz bolesnika.** Muškarac star 53 godine sa blagom hemofilijom A [FVIII 22% (blaga forma – više od 5%–40% od normale)] hospitalizovan je zbog učestalih

anginoznih bolova u miru. Selektivna koronarografija je pokazala tešku trosudovnu koronarnu bolest koja je zahtevala hitnu hiruršku revaskularizaciju miokarda. Kolor dopler krvnih sudova vrata je pokazao hemodinamski značajnu stenozu na desnoj karotidnoj arteriji. Posle konsultacije sa kardiohirurgom, hematologom i vaskularnim hirurgom, zbog povećanog rizika od krvarenja odlučeno je da se hirurška revaskularizacija miokarda i endarterektomija desne karotidne arterije rade u istom aktu. Operacije su urađene uz supstituciju koncentratom faktora VIII. Najpre je urađena endarterektomija desne karotidne arterije, a zatim

je iskorišćena leva arterija mamarija kao graft na levu prednju descendentnu arteriju, kao i dva venska grafta na prvu optuzu u marginalnu granu i zadnje descendentne grane. Tokom intervencije nije bilo hemoragijskih komplikacija, niti potrebe za transfuzijom krvi. Bolesnik je otpušten kući sa antitrombocitnom terapijom (acetilsalicilna kiselina, 50 mg). **Zaključak.** Bolesnici sa hemofilijom nisu zaštićeni od razvoja ateroskleroze. U cilju obezbeđivanja zadovoljavajuće hemostaze, kardiohirurške operacije kod

ovih bolesnika, predstavljaju pravi izazov za ceo medicinski tim. Adekvatna supstitucija koncentratom FVIII osigurava adekvatnu hemostazu i daje mogućnost za primenu antitrombocitne terapije.

Ključne reči:

hemofilija; koronarna bolest; aortokoronarno premošćavanje; endarterektomija a. carotis; hirurgija, kardiovaskularna, procedure; lečenje, ishod.

Introduction

Haemophilia A is the most common hereditary coagulation disorder occurring due to the lack of coagulation factor VIII (FVIII). The life expectancy of persons born with haemophilia, who have access to adequate treatment, should approach the average with the currently available treatment ¹.

It is widely accepted that people with haemophilia have a reduced incidence of coronary artery disease, potentially because of the protective effect of the impaired coagulation against the pathogenic mechanisms of acute coronary syndrome ^{2,3}. Also, data have demonstrated that mortality due to ischaemic heart disease is lower in haemophilia patients than in the general male population ⁴. Advances in managing haemophilia increase the life expectancy and the development of age-related and lifestyle-associated disorders, such as atherosclerosis and ischaemic heart disease ².

Cardiac surgery in these patients presents a unique challenge to medical teams in securing haemostasis.

Case report

A 53-year-old male patient was hospitalized because of frequent chest pain at rest. The patient had a history of

hypertension, hyperlipidemia, and long-term smoking experience. The personal history revealed haemophilia A with FVIII activity around 20%.

Laboratory examination verified decreased activity of factor FVIII [FVIII 22% (normal haemostasis requires at least a quarter (25%) of factor VIII activity)], normal activity of von Willebrand factor (vWF 112%), and prolonged activated partial thromboplastin time (aPTT) 37.5 s (reference range 29.1–41.9 s). He did not have FVIII inhibitors. The patient has been treated with cryoprecipitate in case of joint haemorrhages or dental interventions since childhood. Since 1980, the patients has been treated with FVIII concentrate from human plasma in preparation for tonsillectomy and cholecystectomy.

Following the advice of a haematologist, the patient received 3,000 IU of human FVIII concentrate prior to coronary angiography (Figure 1). After substitution, the level of FVIII was 104%. Catheterization was performed via the right radial artery and revealed a severe three-vessel coronary disease with high degree left main stenosis (Figure 2). It indicated a need for urgent surgical revascularization. There were no haemorrhagic complications after the procedure.

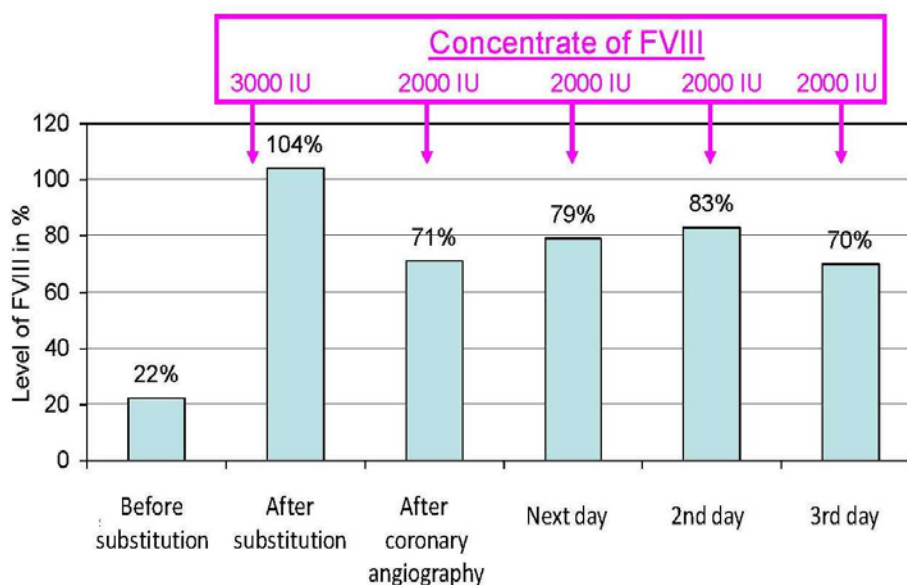


Fig. 1 – Substitution with FVIII concentrate before and after coronary angiography.

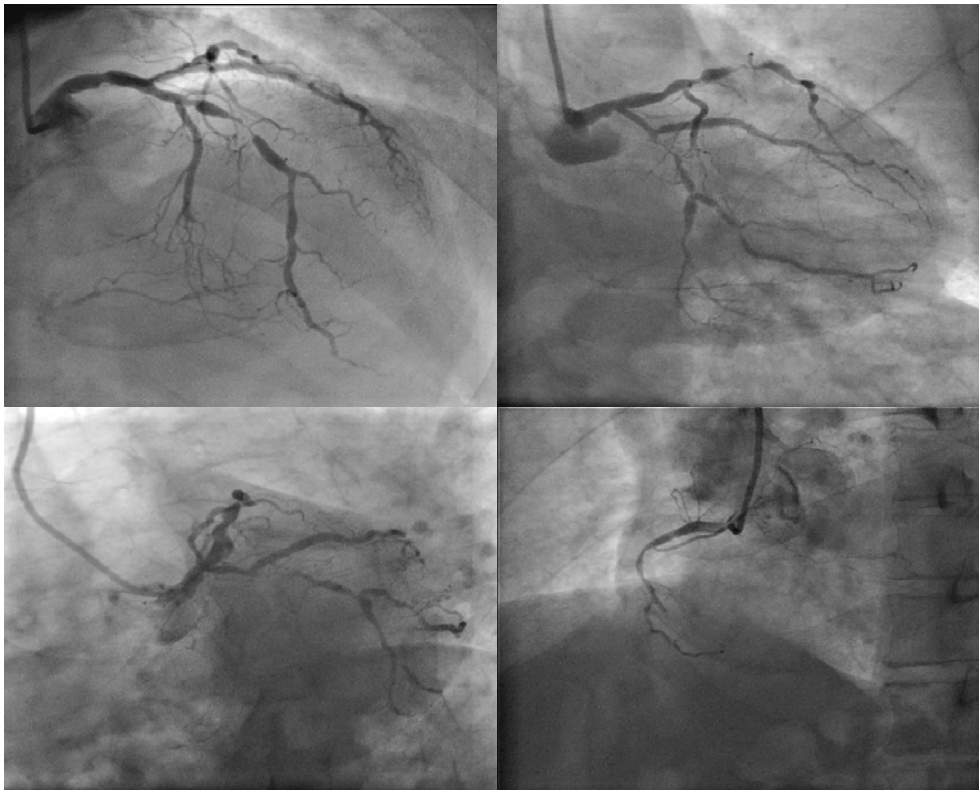

Fig. 2 – Coronary angiography (severe three-vessel coronary disease: LM stenosis 50%, LAD mid 70–90%, Cx prox 90–99%, Cx mid 90–99%, Cx dist 90–99%, OM2 70–90%, RCA prox 70–90%, RCA mid 100%).

LM – left main coronary artery; LAD – left anterior descending artery; Cx – circumflex artery; prox – proximal segment; mid – middle segment; dist – distal segment; OM2 – obtuse marginal 2; RCA – right coronary artery.

In preparation for surgery, according to the existing guidelines and the history of transient ischemic attack less than six months prior to surgery, a color duplex scan of carotid arteries was performed⁵. It showed the existence of ulcerated plaque on the right internal carotid artery that gives haemodynamically significant stenosis of 85%. The computed tomography (CT) scan of carotid arteries and aorta was performed, and the ultrasound findings were confirmed. There were no significant plaques or calcifications in the ascending aorta. Endarterectomy was indicated due to the medical record of the transient ischaemic attack, the characteristic of the plaque, and the degree of stenosis⁶.

In patients with haemophilia, the surgical treatment raises costs due to the need for FVIII administration. A more complex perioperative period and a multidisciplinary approach are required, and there is also an increased bleeding risk. Because of that, simultaneous interventions are advisable when possible. In addition to this, it is known that haemophilic patients can develop anti-FVIII antibodies after 20–50 repeated FVIII administrations, which speaks in favour of a joint operation. After consulting a haematologist, cardiologist, cardiac surgeon, and vascular surgeon, it was concluded that the patient should undergo an endarterectomy and a triple aortocoronary bypass in the same procedure.

Due to an unsuitable radial artery diameter, the quality of preoperative ultrasound screening, and the fact that the

patient was obese (higher risk of deep sternal wound infection is present if both mammary arteries were harvested), a surgeon decided to choose the left mammary artery in addition to the great saphenous vein as the grafts of choice for this procedure. The on-pump approach was selected over the off-pump after analyzing the coronary anatomy and the fact that there were no significant calcifications in the ascending aorta (with no significant risk of cross-clamp injury).

Before, during, and after surgery, the patient was constantly monitored by a haematologist. Every 30 min during surgery, the level of FVIII and aPTT were measured. FVIII was given according to given values. During the total heparinisation, activated clotting time was used to measure the heparinisation level. For the entire perioperative period, FVIII level was kept in a normal range.

Just before the surgery, the patient received a bolus of 3,500 IU of FVIII. After fifteen minutes, the level of FVIII was 101%, and after one hour, 90%. During that time, an endarterectomy was performed on the right carotid artery and the great saphenous vein from the right leg was harvested for the use as a venous graft. After that, a median sternotomy was done and the left mammary artery was harvested. Systemic heparin was given in 30,000 units and the extracorporeal circulation (ECC) was started. The anticoagulation activity of heparin was monitored by

activated clotting time (ACT) and protamine sulphate was given twice to maintain ACT around 400 s. During the procedure, FVIII was added several times (Figure 3). The patient underwent implantation of the left mammary artery to the left anterior descending artery (LAD) and two vein grafts to the first obtuse marginal (OM) artery and posterior descending (PD). There was no need for blood transfusion

and antifibrinolytics were not prescribed. ECC lasted for 91 min, and the total revascularization time was 4 h. At the end of the procedure, the level of FVIII was 60%.

On the first postoperative day, aspirin in low-dose of 50 mg and low-molecular-weight heparin were introduced to the therapy. The level of FVIII was between 83% and 104% (Figure 4).

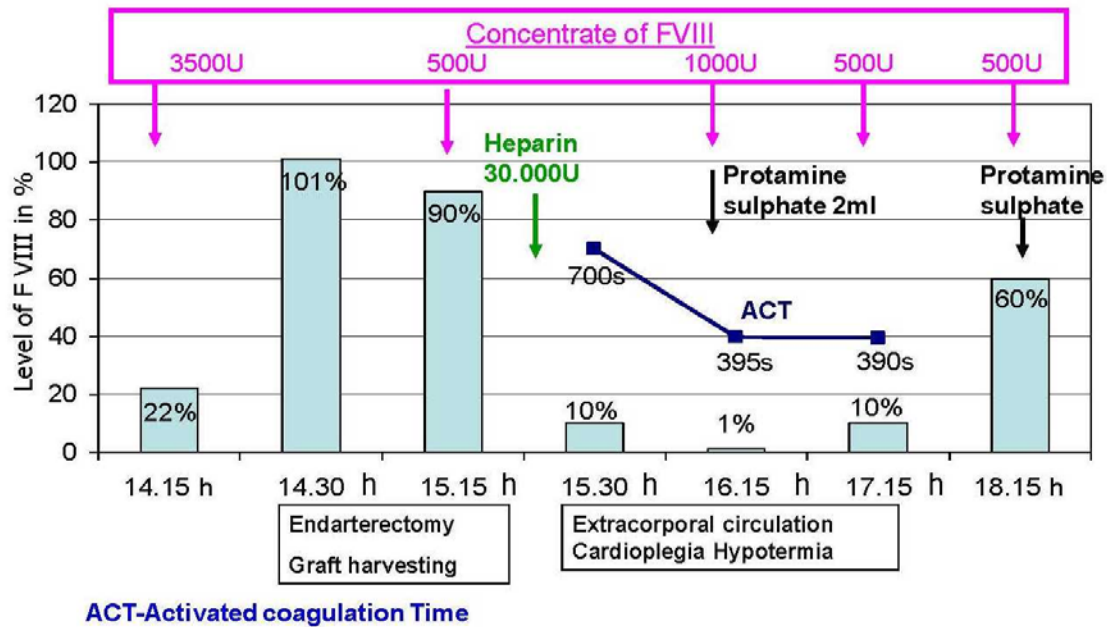


Fig. 3 – Substitution with FVIII concentrate before and during the surgery.

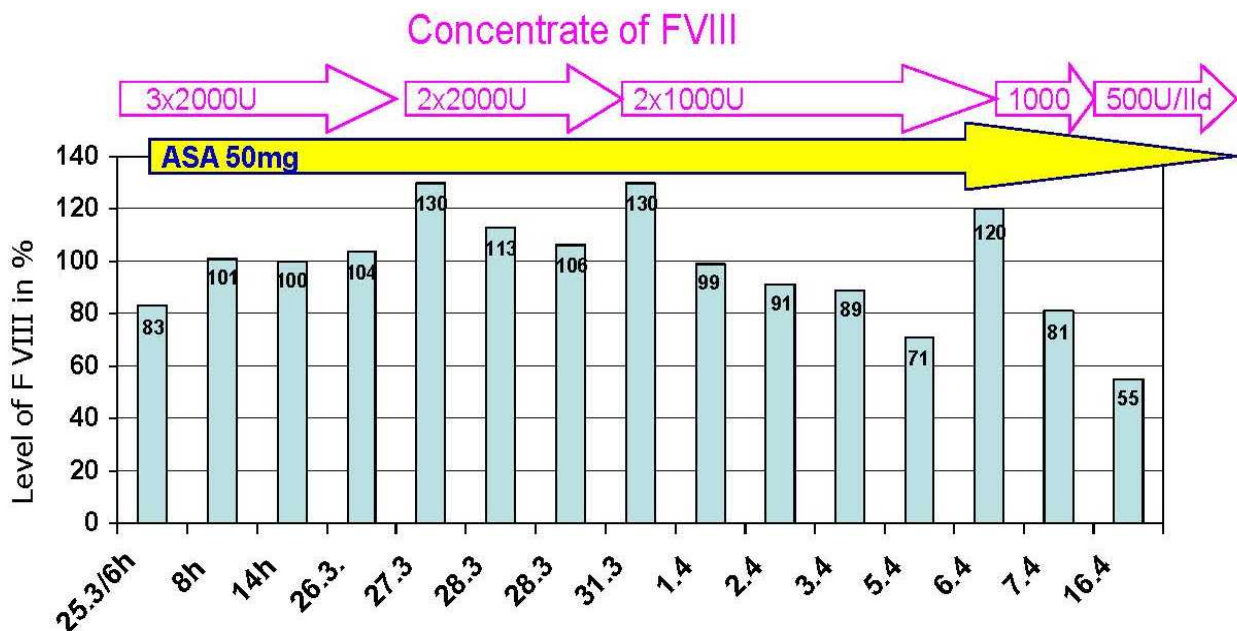


Fig. 4 – Substitution with FVIII concentrate after surgery. ASA – acetylsalicylic acid.

From the second to the sixth postoperative day, $2 \times 2,000$ units of FVIII were prescribed. In the coming days, the dose was reduced (Figure 4). There was no excessive bleeding in the postoperative period.

At discharge, the level of FVIII was 55%. The patient was discharged with aspirin 50 mg, a statin, and a beta-blocker. The haematologist decided that the patient should not receive FVIII as long as its levels stay above 30%.

Fourteen months after the surgery, the level of FVII was 37% and during that period there were no haemorrhagic complications.

Discussion

As the haemophilia population is getting older, studies have established that cardiovascular mortality is three times more common as a cause of death⁷, but that mortality is 60% lower than in the general population^{8–11}. Several potential reasons may explain the low incidence of coronary artery disease in patients with haemophilia. These patients have hypocoagulable status and are significantly less likely to form a thrombotic mass. They also have a less established atheroma in blood vessels¹². However, the patients with haemophilia might not be protected from atherosclerosis, as demonstrated by clinical studies¹³ and autopsy reports on haemophiliacs with fatal myocardial infarction showing extensive atherosclerotic lesions and only rarely fresh thrombi¹⁴.

Patients with haemophilia have an increased tendency to bleed, and, therefore, any invasive procedure is associated with an increased risk of hemorrhagic complications. Artery incision is confined with a high risk of local complications, but it can be effectively reduced by substituting a coagulation factor or by choosing access via radial artery for catheterization¹⁵, as was the case with our patient. Considering that different complications are possible during invasive procedures, and sometimes urgent surgery is necessary, it was decided that higher doses of FVIII be given.

However, applying the missing coagulation growth factor may increase the risk of acute thrombosis in patients with unstable atherosclerotic plaques. Girolami et al.¹⁵ studied 36 cases of acute coronary syndrome in patients with haemophilia A. In most cases, the event occurred during or after the infusion of recombinant FVIII, desmopressin, and prothrombin complex concentrates¹⁴.

In addition, one of the treatment-related complications occurring mainly in haemophilia A patients is the

development of an inhibitor, usually an IgG antibody, which is directed against the specific deficient factor and may occur shortly after the replacement therapy has been initiated¹⁶.

Cardiac surgery constitutes a major haemostatic challenge because of sternotomy, the need for total heparinization, ECC, mild hypothermia, and cardiac arrest. However, there is no uniform protocol for the substitution of FVIII that can be applied in a bolus or an infusion¹⁷. According to the World Federation of Haemophilia recommendations, patients with haemophilia A undergoing major surgery should be supplemented with FVIII before the procedure to achieve the level of 80%–100% of FVIII activity¹.

Procedures using cardiopulmonary bypass incorporated standard heparinization protocols in many patients with haemophilia described in the literature, after 100% correction of factor levels by a bolus or continuous administration of factor concentrates^{25–31}.

During surgery, the level of FVIII was monitored and the concentrate was added according to values gathered. On heparin induction, the level of FVIII decreased to 10% and after that to 1%. Then, the patient received protamine-sulphate and 500 IU more of FVIII. After that, the level of FVIII increased to 60%. The level of FVIII increased due to the substitution and neutralization of heparin with protamine-sulphate.

Antiplatelet therapies are important for preventing thrombosis after cardiac surgery³⁰. Haemophilia is not associated with abnormalities of platelet number or platelet function. However, antiplatelet therapy can increase the haemorrhagic tendency¹⁹. To minimize these risks, the clotting factor deficiency has to be corrected. As coronary artery bypass grafting and patients with coronary disease are required to be on single or dual antiplatelet therapy, for haemophilic patients, the use of aspirin in 50 mg dosage is recommended as long as FVIII is above 30% with regular measurements of FVIII level. Dual antiplatelet therapy is discouraged in these patients³¹.

Conclusion

Patients with haemophilia are not protected from the development of atherosclerosis. Cardiac surgery in these patients presents a unique challenge to medical teams in securing haemostasis. Adequate substitution with FVIII concentrate provides adequate haemostasis and the possibility for treatment with antiplatelet therapy.

REFERENCES

1. *Srinastava A, Brewer AK, Mauser-Bunschoten EP, Key NS, Kitchen S, Llinas A*, et al. Treatment Guidelines Working Group on Behalf of The World Federation Of Hemophilia. Guidelines for the management of hemophilia. *Haemophilia* 2013; 19(1): e1–47.
2. *Mafrić A, Baudo F*. Hemophilia and percutaneous coronary interventions. *Ital Heart J* 2003; 4(10): 731–3.
3. *Bilora F, Dei Rossi C, Girolami B, Casonato A, Zanon E, Bertomoro A*, et al. Do hemophilia A and von Willebrand disease protect against carotid atherosclerosis? A comparative study between coagulopathics and normal subjects by means of carotid echo-color Doppler scan. *Clin Appl Thromb Hemost* 1999; 5(4): 232–5.
4. *Rosendaal FR, Briët E, Stibbe J, van Herpen G, Leuven JA, Hofman A*, et al. Haemophilia protects against ischaemic heart disease: a study of risk factors. *Br J Haematol* 1990; 75(4): 525–30.

5. *Aboyans V, Ricco JB, Bartelink MEL, Björck M, Brodmann M, Cohnert T, et al.* ESC Scientific Document Group. 2017 ESC Guidelines on the Diagnosis and Treatment of Peripheral Arterial Diseases, in collaboration with the European Society for Vascular Surgery (ESVS): Document covering atherosclerotic disease of extracranial carotid and vertebral, mesenteric, renal, upper and lower extremity arteries. Endorsed by: the European Stroke Organization (ESO) The Task Force for the Diagnosis and Treatment of Peripheral Arterial Diseases of the European Society of Cardiology (ESC) and of the European Society for Vascular Surgery (ESVS). *Eur Heart J* 2018; 39(9): 763–816.
6. *Neumann FJ, Sousa-Uva M, Ahlsson A, Alfonso F, Banning AP, Benedetto U, et al.* ESC Scientific Document Group. 2018 ESC/EACTS Guidelines on myocardial revascularization. *Eur Heart J* 2019; 40(2): 87–165.
7. *Mannucci PM, Schutgens RE, Santagostino E, Mauser-Bunschoten EP.* How I treat age-related morbidities in elderly patients with hemophilia. *Blood* 2009; 114(26): 5256–63.
8. *Soucie JM, Nuss R, Evatt BG, Abdelhak A, Cowan L, Hill H, et al.* Mortality among males with hemophilia: relations with source of medical care. The Hemophilia Surveillance system Project Investigators. *Blood* 2000; 96(2): 437–42.
9. *Darby SC, Kan SW, Spooner RJ, Giangrande PL, Hill FG, Hay CR, et al.* Mortality rates, life expectancy, and causes of death in people with hemophilia A or B in the United Kingdom who were not infected with HIV. *Blood* 2007; 110(3): 815–25.
10. *Plug I, Van Der Bom JG, Peters M, Mauser-Bunschoten EP, de Goede-Bolder A, Heijnen L, et al.* Mortality and causes of death in patients with hemophilia, 1992–2001: a prospective cohort study. *J Thromb Haemost* 2006; 4: 510–6.
11. *Triemstra M, Rosendaal FR, Smit C, Van der Ploeg HM, Briët E.* Mortality in patients with hemophilia. Changes in a Dutch population from 1986 to 1992 and 1973 to 1986. *Ann Intern Med* 1995; 123(11): 823–7.
12. *Berger K, Schopohl D, Lowe G, Holme PA, Taii RC, Combescuré C, et al.* How to compare cardiovascular disease and risk factors in elderly patients with haemophilia with general population. *Haemophilia* 2016; 22(5): e406–16.
13. *Biere-Rafji S, Zwiens M, Peters M, van der Meer J, Rosendaal FR, Büller HR, et al.* The effect of haemophilia and von Willebrand disease on arterial thrombosis: a systematic review. *Neth J Med* 2010; 68(5): 207–14.
14. *Srámek A, Reiber JH, Gerrits WB, Rosendaal FR.* Decreased coagulability has no clinically relevant effect on atherogenesis: observations in individuals with a hereditary bleeding tendency. *Circulation* 2001; 104(7): 762–7.
15. *Girolami A, Ruzzone E, Fabris F, Varvarikis C, Sartori R, Girolami B.* Myocardial infarction and other arterial occlusions in hemophilia a patients. A cardiological evaluation of all 42 cases reported in the literature. *Acta Haematol* 2006; 116(2): 120–5.
16. *Smolka G, Kulach A, Dabek J, Szulc A, Gasiór Z.* Percutaneous coronary intervention with stent implantation in haemophilic A patient with unstable angina. *Haemophilia* 2007; 13(4): 428–31.
17. *Bhave P, McGiffin D, Shaw J, Walsh M, McCarthy P, Tran H, et al.* Guide to performing cardiac surgery in patients with hereditary bleeding disorders. *J Card Surg* 2015; 30(1): 61–9.
18. *Kim DK, Kim DI, Kim MS, Lee EJ, Kim YB, Cho HJ, et al.* Successful percutaneous coronary intervention for acute coronary syndrome in a patient with severe hemophilia a. *Korean Circ J* 2010; 40(10): 527–9.
19. *Tang M, Wierup P, Terp K, Ingerslev J, Sørensen B.* Cardiac surgery in patients with haemophilia. *Haemophilia* 2009; 15(1): 101–7.
20. *MacKinlay N, Taper J, Renisson F, Rickard K.* Cardiac surgery and catheterization in patients with haemophilia. *Haemophilia* 2000; 6(2): 84–8.
21. *Rodriguez V, Burkhart HM, Schmidt KA, Pruthi RK.* Hemostatic management of an infant with severe hemophilia A and tetralogy of Fallot for cardiac bypass surgery. *Pediatr Blood Cancer* 2010; 55(7): 1399–401.
22. *Gasparović H, Zupancić-Salek S, Brida V, Dulčić G, Jelić I.* Aortic valve replacement in a patient with severe hemophilia. *Coll Antropol* 2007; 31(1): 355–7.
23. *Kaminishi Y, Aizawa K, Saito T, Misawa Y, Madoiva S, Sakata Y.* Modified Bentall operation in a patient with hemophilia A. *Jpn J Thorac Cardiovasc Surg* 2003; 51(2): 68–70.
24. *Donahue BS, Emerson CW, Slaughter TF.* Case 1--1999. Elective and emergency cardiac surgery on a patient with hemophilia B. *J Cardiothorac Vasc Anesth* 1999; 13(1): 92–7.
25. *Meagher PD, Rickard KA, Richards JG, Baird DK.* Aortic and mitral valve replacement in a patient with severe haemophilia A. *Aust N Z J Med* 1981; 11(1): 76–9.
26. *Murugan SJ, Viswanathan S, Thomson J, Parsons JM, Richards M.* Heart surgery in infants with hemophilia. *Ann Thorac Surg* 2006; 81(1): 336–9.
27. *Eren A, Friedl R, Hannekum A, Gulbins H.* Cardiac surgery in a patient with haemophilia A. *Thorac Cardiovasc Surg* 2006; 54(3): 212–4.
28. *Stine KC, Becton DL.* Use of factor VIII replacement during open heart surgery in a patient with haemophilia A. *Haemophilia* 2006; 12(4): 435–6.
29. *De Bels D, Demeere JL, Dugauquier J, Louis P, Van der Vorst E.* Continuous infusion of factor VIIIc during heart surgery in a patient with haemophilia A. *Eur J Anaesthesiol* 2004; 21(12): 984–6.
30. *Scharfman WB, Rauch AE, Ferraris V, Burkart PT.* Treatment of a patient with factor IX deficiency (hemophilia B) with coronary bypass surgery. *J Thorac Cardiovasc Surg* 1993; 105(4): 765–6.
31. *Kanellopoulou T, Nomikou E.* Replacement therapy for coronary artery bypass surgery in patients with hemophilia A and B. *J Card Surg* 2018; 33(2): 76–82.

Received on October 10, 2018.

Revised on December 29, 2018.

Revised on January 04, 2019.

Accepted on January 10, 2019.

Online First January, 2019.